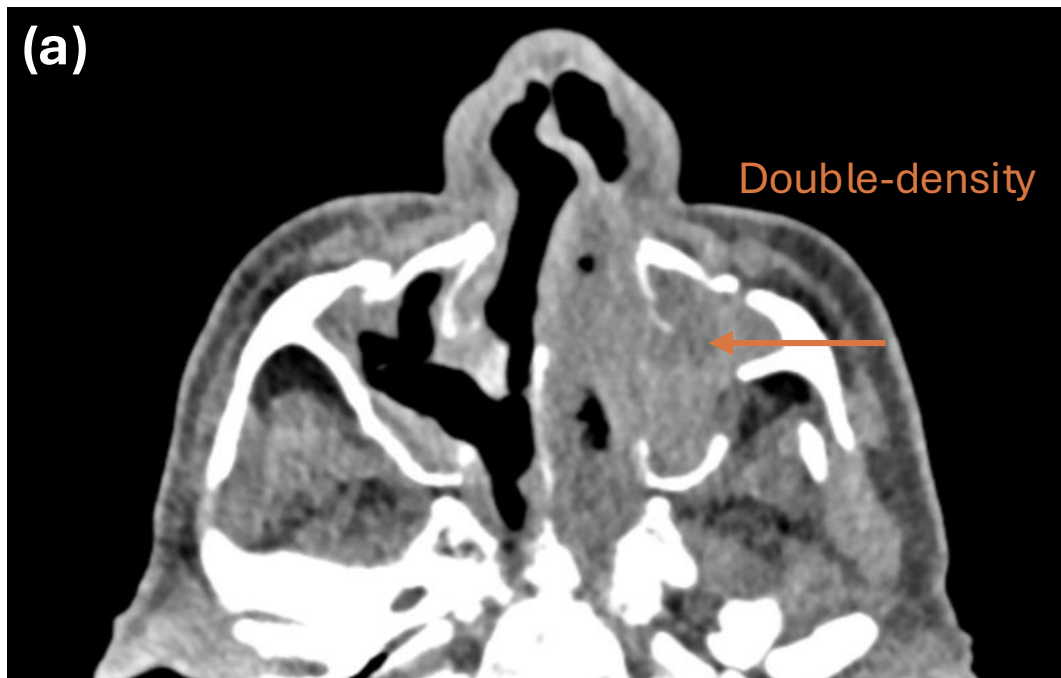
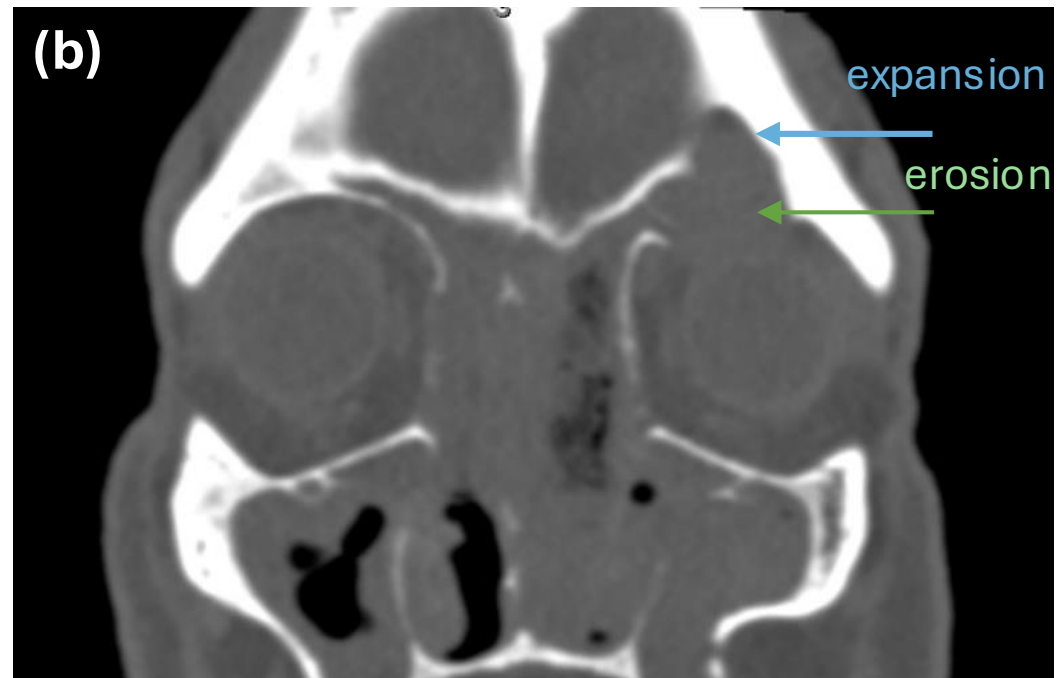

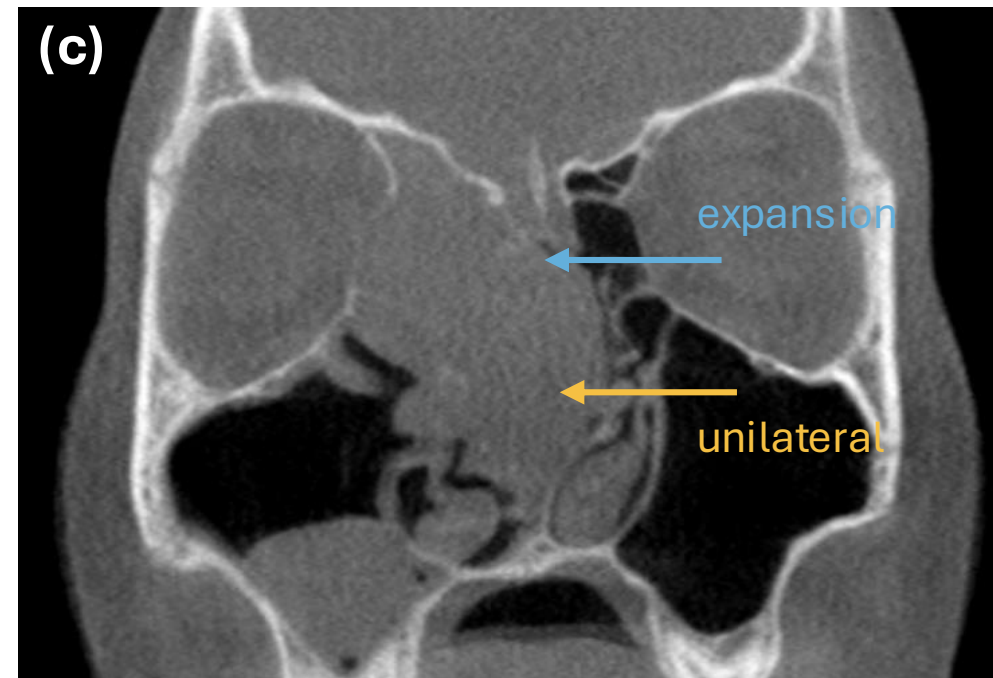
CT Axial



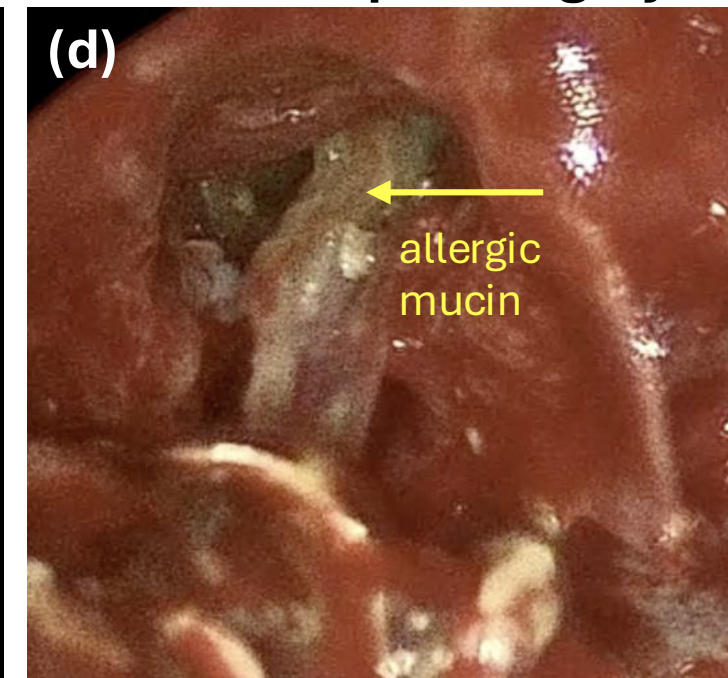
CT Coronal



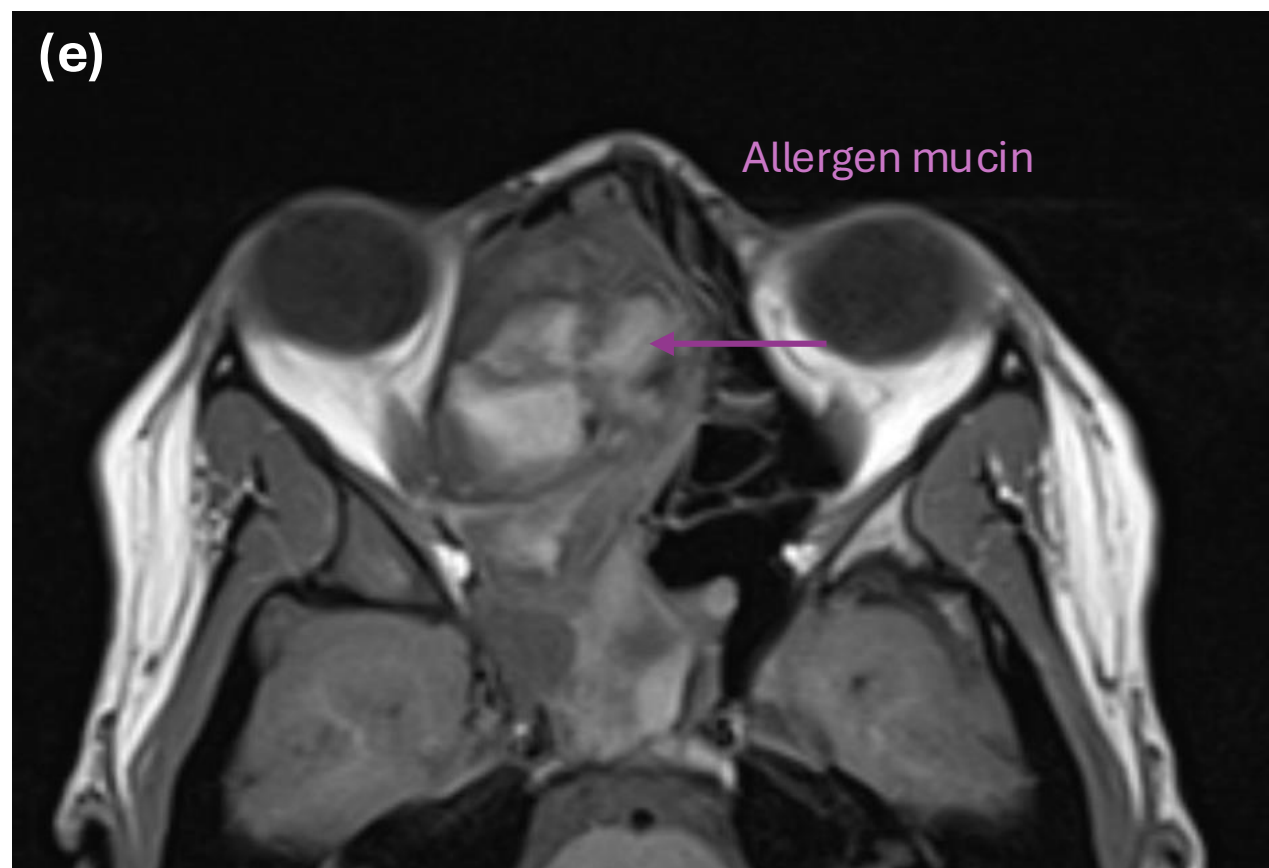
CT Coronal



Endoscopic Surgery



MRI T1-weighted Axial



MRI T2-weighted Axial

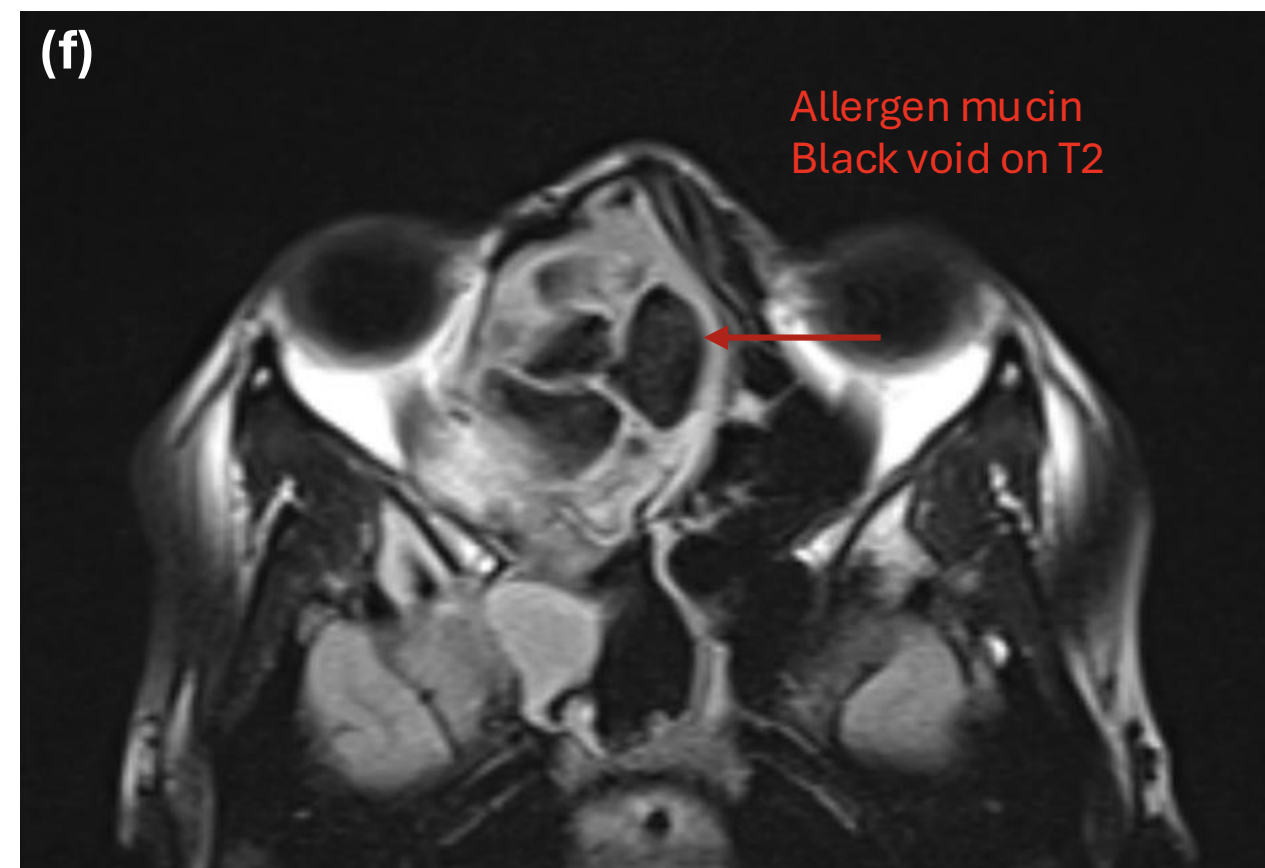


Figure 1. Radiological features of AFRS from CT (1a-c), endoscopic surgery (1d) and MRI imaging (1e-f).